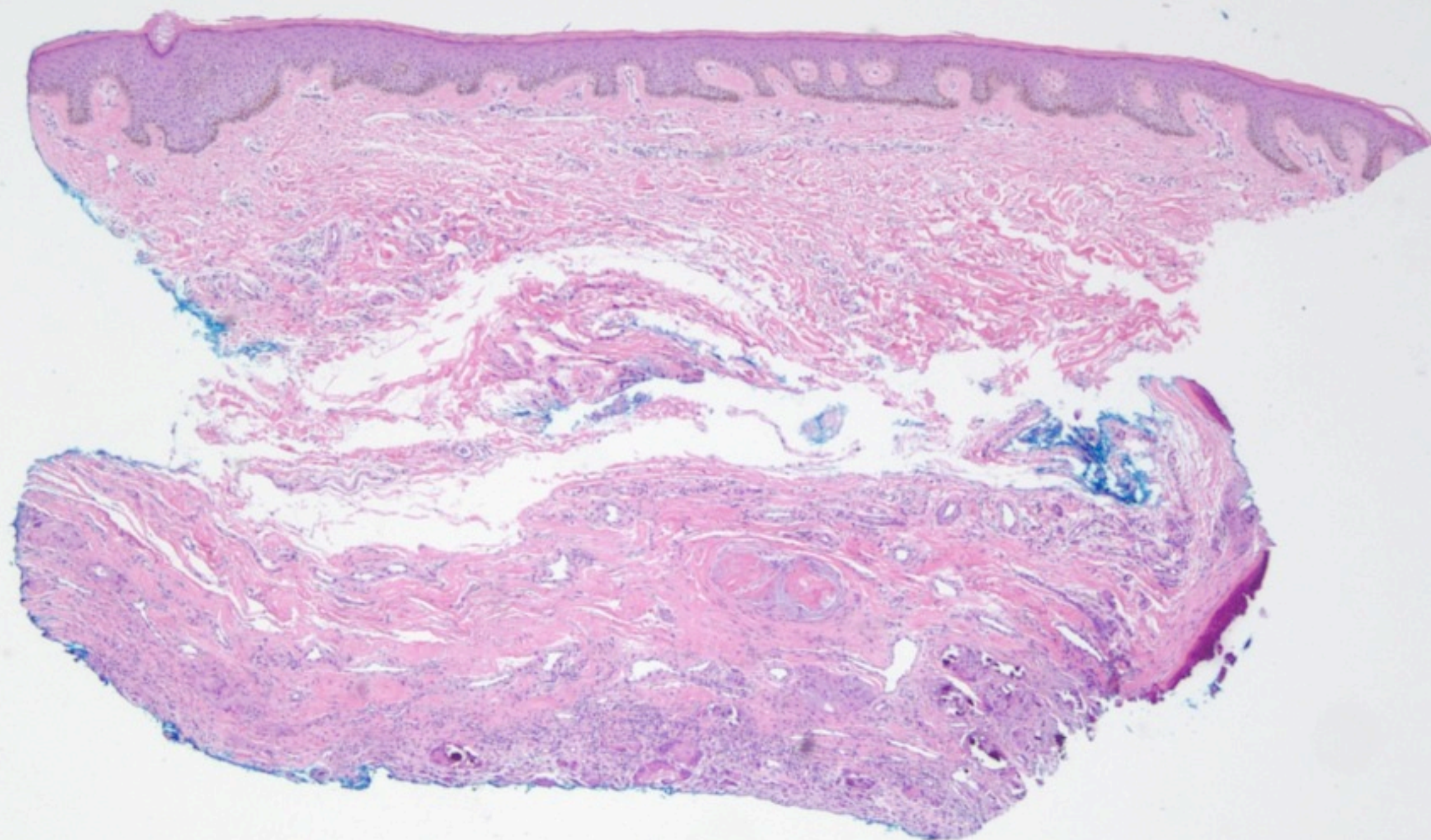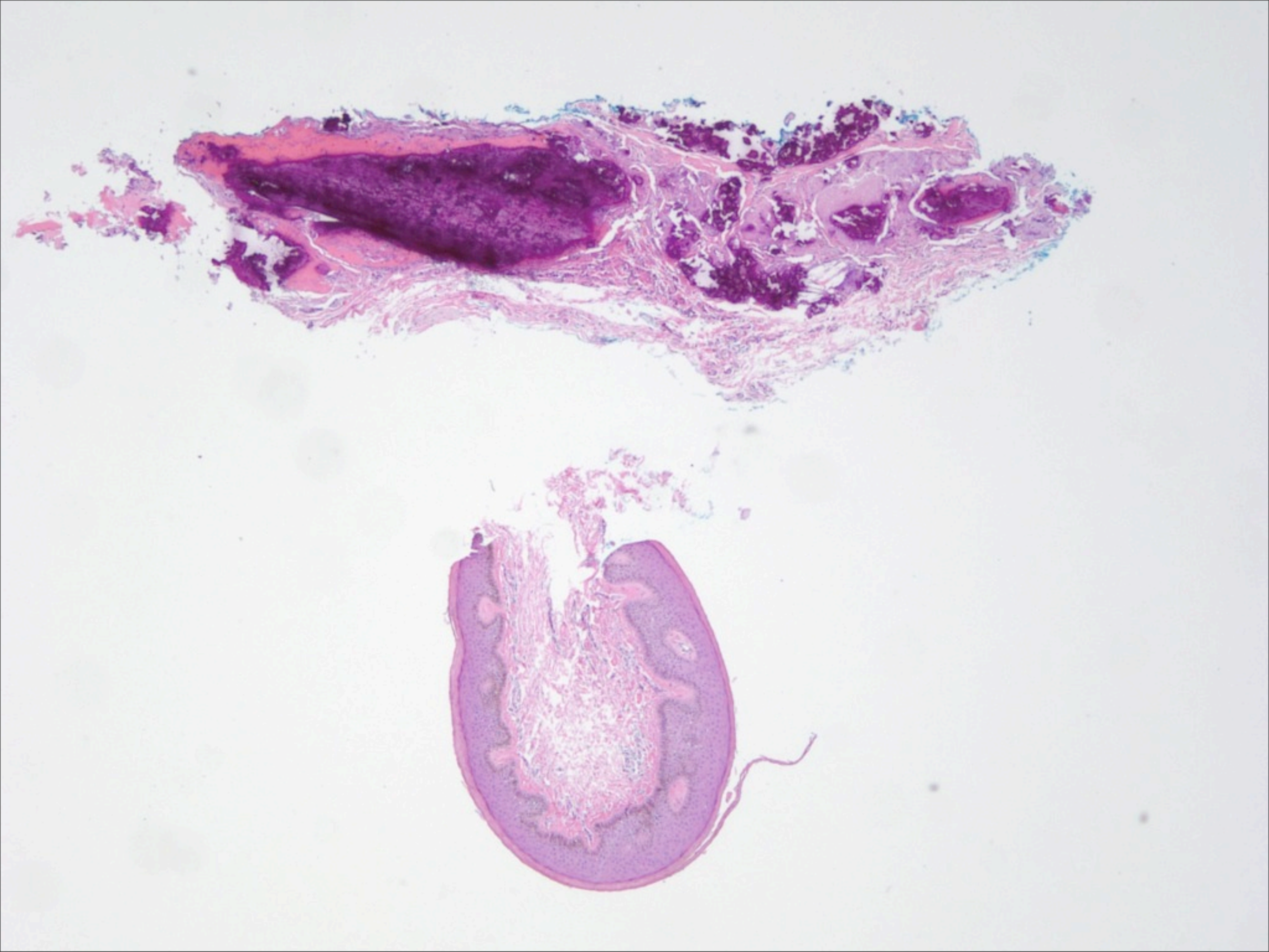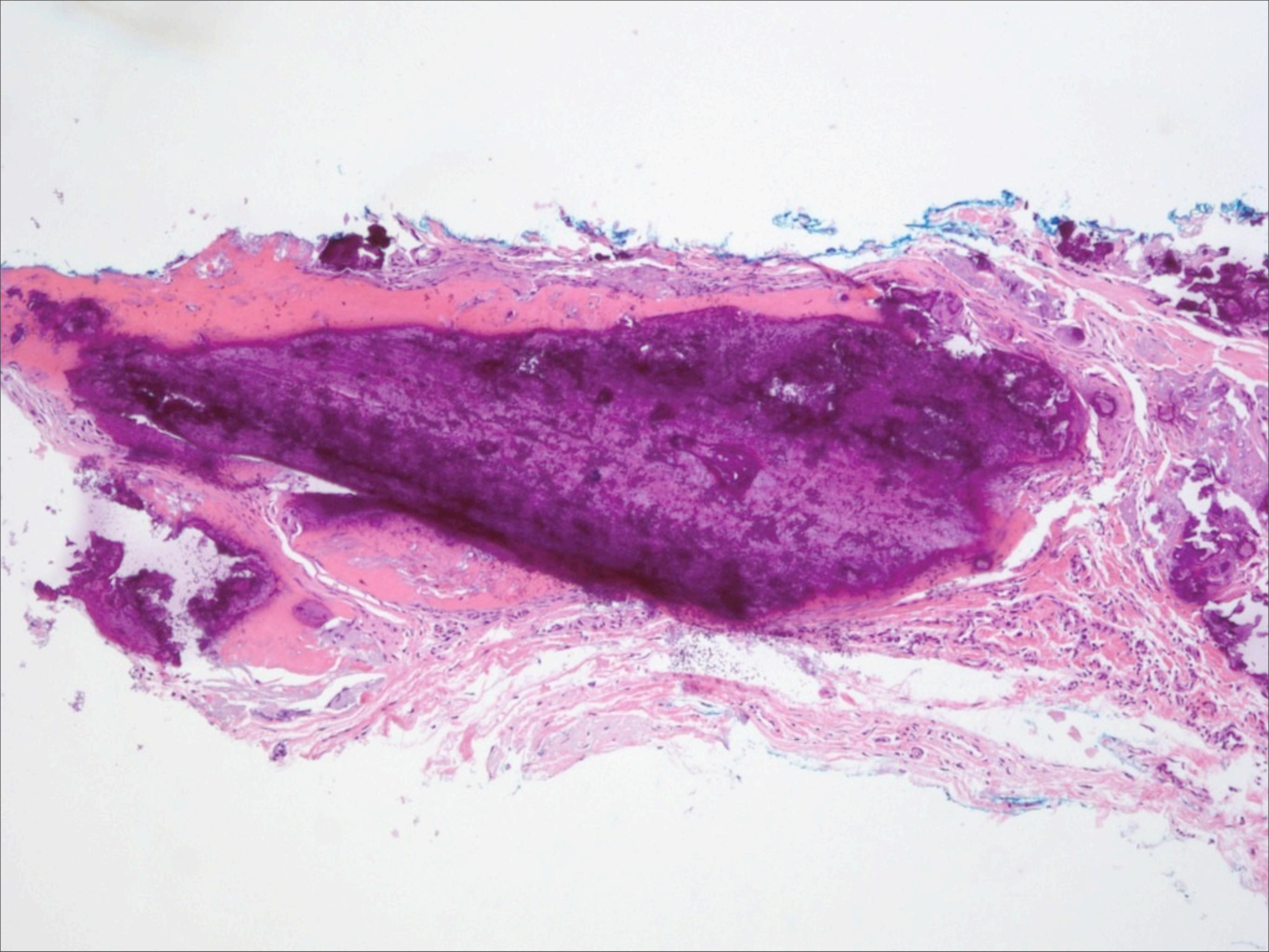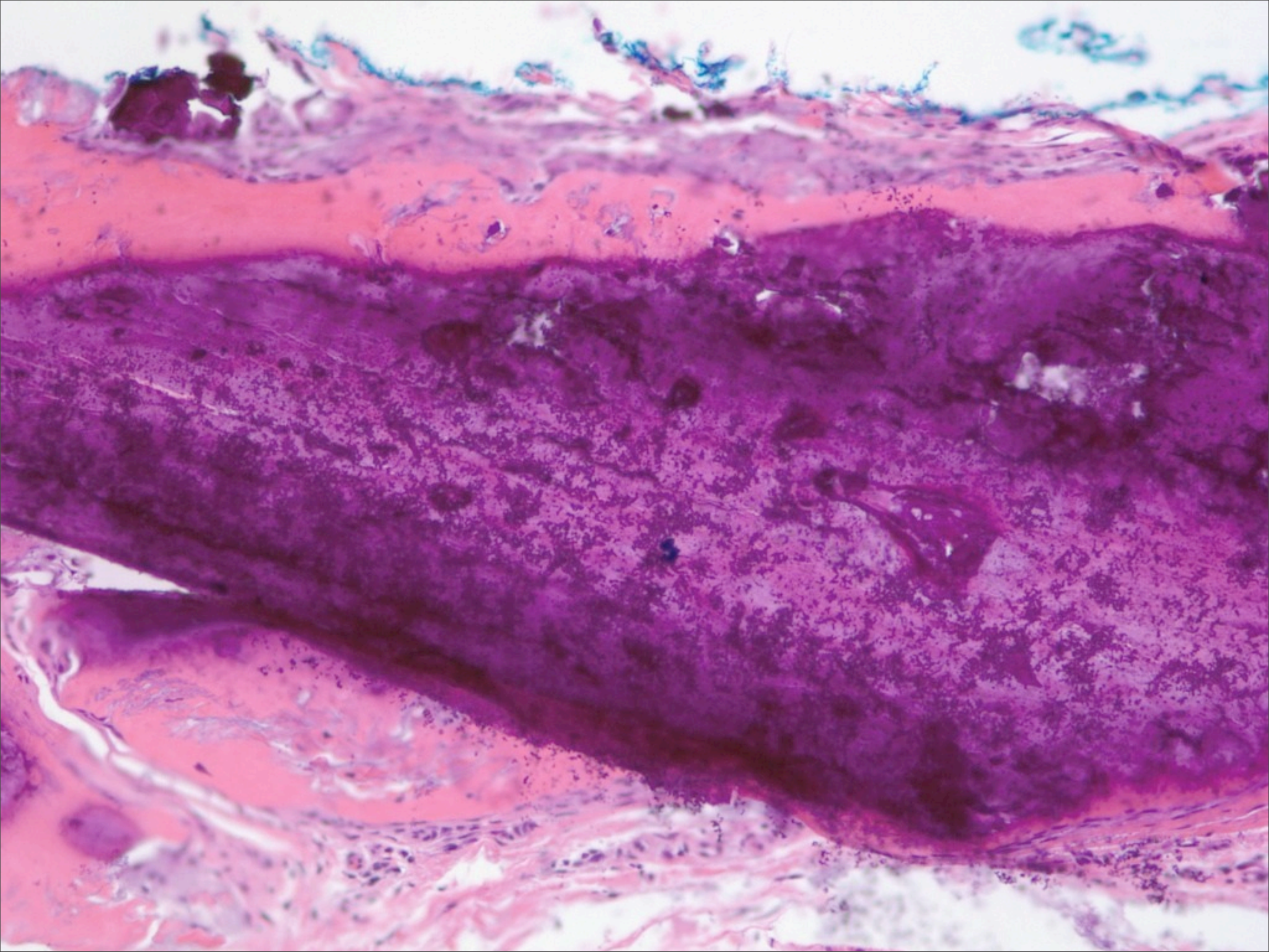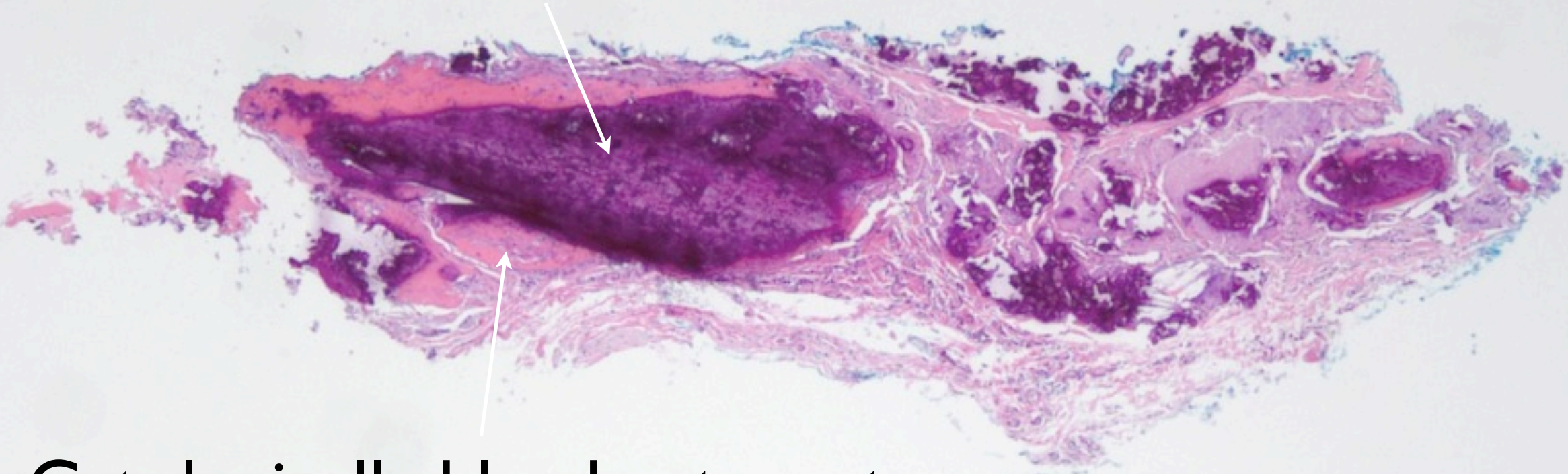


Osteoma Cutis

Mature bone with calcifications



Cytologically bland osteocytes

